

LETTER TO THE EDITOR

Nucleus subputaminalis: neglected part of the basal nucleus of Meynert

Marina Boban, Ivica Kostovic and Goran Simic

Department of Neuroscience, School of Medicine, Croatian Institute for Brain Research, Zagreb University, Croatia

Correspondence to: Professor Goran Simic, Department of Neuroscience, School of Medicine, Croatian Institute for Brain Research, Zagreb University, Croatia

E-mail: gsimic@hiim.hr

doi:10.1093/brain/awl025

Received November 19, 2005. Accepted January 16, 2006

With much pleasure we have read the article written by Stephan Teipel and collaborators (Teipel *et al.*, 2005) entitled *Measurement of basal forebrain atrophy in Alzheimer's disease using MRI* published on July 13 in *Brain*. We cannot but agree that the automated technique of image regression analysis implemented to the analysis of proton density weighted structural MRI of the basal forebrain presented in the article might have excellent value for *in vivo* determination of the time course of basal forebrain cholinergic neuronal degeneration as well as its temporal relationship to cortical atrophy in patients with Alzheimer's disease.

However, we would like to draw the reader's attention to Fig. 2A in Teipel *et al.* (2005). In plates 103 out of 205 and 102 out of 203 in this figure, the cluster of magnocellular cholinergic neurons located in the anterior part of the basal forebrain (ventrolaterally to the anterior commissure) could not be recognized by authors and was designated as 'Ch4 p?'. This particular cell group, which is topographically, cytochemically and cytoarchitectonically intimately related to the basal nucleus, was described in the human and anthropoid monkey brain and named as nucleus subputaminalis (NSP) by Giuseppe Ayala. He published his findings many years ago in your esteemed journal (Ayala, 1915).

Although it has been neglected in most classical (such as Kölliker, 1896 and Brockhaus, 1942) as well as more current studies (except Hedreen *et al.*, 1984; Kostovic, 1986; Kracun and Rosner, 1986; Ulfing, 1989; Halliday *et al.*, 1993), a recent more detailed analysis of the NSP in 36 neurologically normal subjects ranging from 15 weeks of gestation to 71 years of age have revealed its precise location at all levels (Simic *et al.*, 1999) (Fig. 1). Moreover, at the most rostralateral levels we

have found the previously undescribed component of the lateral subdivision of the NSP (Simic *et al.*, 1999). This part of the NSP has not been described in non-human primates (Gorry, 1963; Divac 1975).

The obviously larger size of NSP on the left side at the most rostral and anterointermediate levels (Halliday *et al.*, 1993; Simic *et al.*, 1999), the ascension of subputaminal cholinergic fibres through the external capsule (Kostovic, 1986) towards the inferior frontal gyrus (Simic *et al.*, 1999), its most progressive phylogenetic cytochemical properties (Simic *et al.*, 1999) and the most protracted development among all the magnocellular aggregations within the basal forebrain (Kracun and Rosner, 1986) strongly suggest that the NSP is human specific and connected with the cortical speech area (Simic *et al.*, 1999). This finding gives rise to many hypotheses about the possible role of the NSP in various neurological, neurodegenerative and psychiatric disorders, particularly primary progressive aphasia (Mesulam disease), Alzheimer's disease and schizophrenia (Heimer, 2000).

While there is a whole body of data for pathological changes of the main part of the basal nucleus, the pathology of NSP was not studied. Since it seems today that the most consistent determinant of pathology in Alzheimer's disease is the anatomical localization of a neuron, we are convinced that Ayala himself was far beyond his time when he believed that pathology of the NSP might differ significantly from pathology of the main part of the basal nucleus. To give honour to this remarkable author who was first to describe NSP, we suggest the eponym NSP of Ayala.

In conclusion, we recommend that the designation 'Ch4 p?' in the article by Teipel *et al.* (2005) should be replaced with

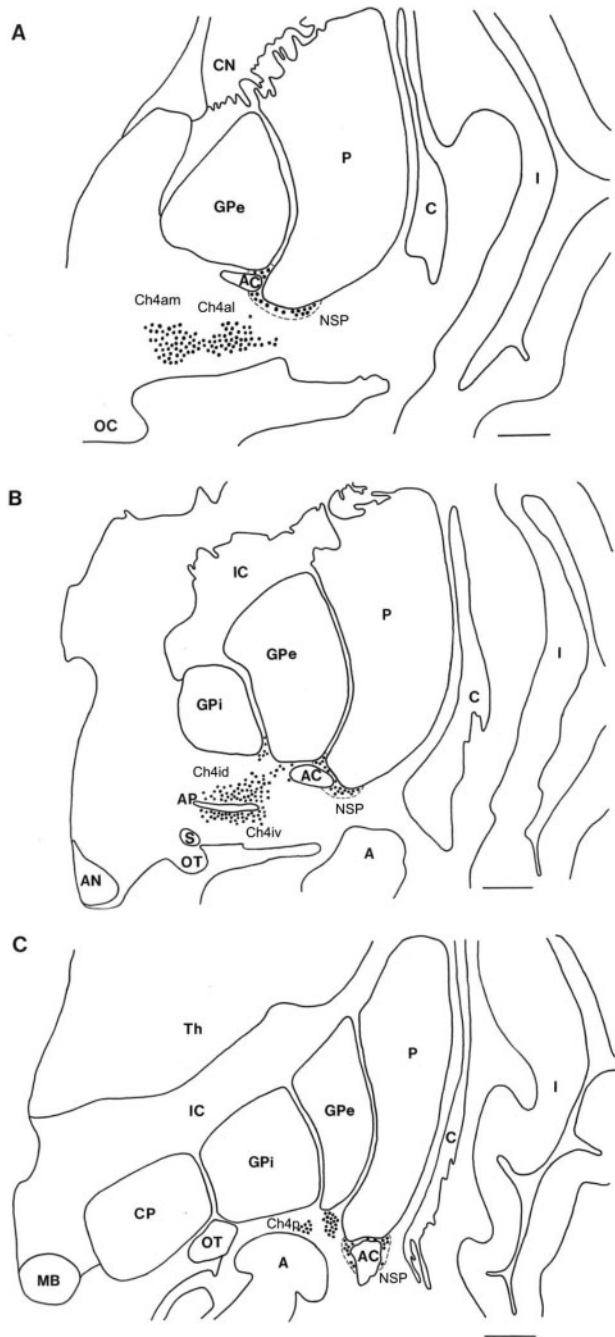


Fig. 1 (A–C) Schematic representation of the subputaminal nucleus (NSP). **(A)** Anterior (septal-chiasmatic) level. **(B)** Intermediate (tubero-infundibular) level. **(C)** Posterior (pre-mammillary) level. Scale bars = 5 mm. CN = caudate nucleus; P = putamen; C = claustrum; I = insular cortex; Gpe = globus pallidus, external segment; IC = internal capsule; AC = anterior commissure; NSP = nucleus subputaminalis; Ch4am = anteromedial division of the cholinergic cell group 4; Ch4al = anterolateral division of the cholinergic cell group 4; OC = optic chiasm; Gpi = globus pallidus, internal segment; Ch4id = intermediodorsal division of the cholinergic cell group 4; Ch4iv = intermedioventral division of the cholinergic cell group 4; AP = ansa peduncularis; S = supraoptic nucleus; OT = tractus opticus; AN = anterior nucleus of hypothalamus; A = amygdala; Ch4p = posterior division of the cholinergic cell group 4; Th = thalamus; CP = cerebral peduncle; MB = mamillary body.

the ‘NSP’ (NSP of Ayala). Future studies on the basal fore-brain should more carefully investigate this potentially very important part of the basal nucleus.

References

- Ayala G. A hitherto undifferentiated nucleus in the forebrain (nucleus subputaminalis). *Brain* 1915; 37: 433–8.
- Brockhaus H. Vergleichend-anatomische Untersuchungen über den Basalkernkomplex. *J Psychol Neurol* 1942; 51: 57–95.
- Divac I. Magnocellular nuclei of the basal forebrain project to neocortex, brainstem and olfactory bulb. Review of some functional correlates. *Brain Res* 1975; 93: 385–98.
- Gorry JD. Studies on the comparative anatomy of the ganglion basale of Meynert. *Acta Anat (Basel)* 1963; 55: 51–104.
- Halliday GM, Cullen K, Cairns MJ. Quantitation and three-dimensional reconstruction of Ch4 nucleus in the human basal forebrain. *Synapse* 1993; 15: 1–16.
- Hedreen JC, Struble RG, Whitehouse PJ, Price DL. Topography of the magnocellular basal forebrain system in human brain. *J Neuropathol Exp Neurol* 1984; 43: 1–21.
- Heimer L. Basal forebrain in the context of schizophrenia. [Review]. *Brain Res Rev* 2000; 31: 205–35.
- Kölliker A, editor. *Handbuch der Gewebelehre des Menschen. Für Ärzte und Studierende. Nervensystem des Menschen und der Thiere, Vol. 2.* Leipzig: Engelmann; 1896.
- Kostovic I. Prenatal development of nucleus basalis complex and related fiber systems in man: a histochemical study. *Neuroscience* 1986; 17: 1047–77.
- Kracun I, Rosner H. Early cytoarchitectonic development of the anlage of the basal nucleus of Meynert in the human fetus. *Int J Dev Neurosci* 1986; 4: 143–9.
- Simic G, Mrzljak L, Fucic A, Winblad B, Lovric H, Kostovic I. Nucleus subputaminalis (Ayala): the still disregarded magnocellular component of the basal forebrain may be human specific and connected with the cortical speech area. *Neuroscience* 1999; 89: 73–89.
- Teipel SJ, Flatz WH, Heinsen H, Bokde AL, Schoenberg SO, Stockel S, et al. Measurement of basal forebrain atrophy in Alzheimer’s disease using MRI. *Brain* 2005; 128: 2626–44.
- Ulfing N. Configuration of the magnocellular nuclei in the basal forebrain of the human adult. *Acta Anat (Basel)* 1989; 134: 100–5.